

Diagnostic Imaging in Chiropractic Practice The WAVE 2019 part 2

Jamie P. Motley, MS, DC, DACBR



LIFE CHIROPRACTIC
COLLEGE WEST

Postgraduate & Continuing Education

<http://ce.lifewest.edu> | 510.780.4508 | conted@lifewest.edu

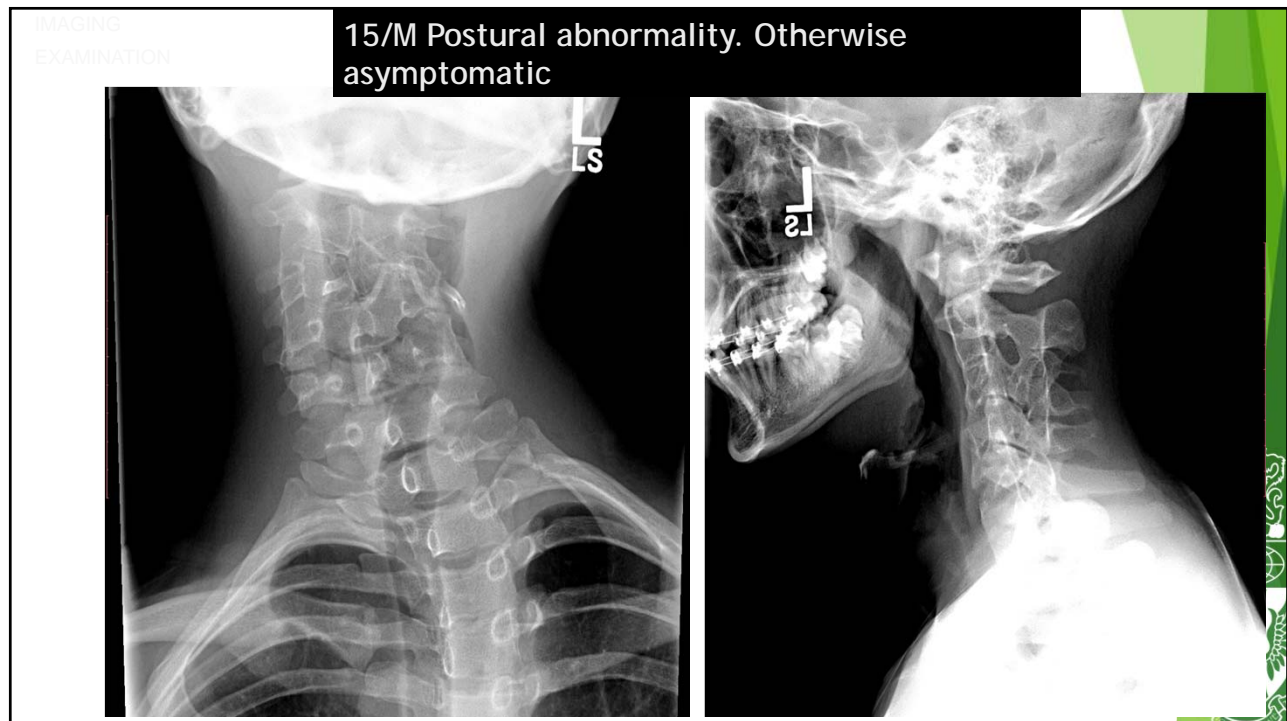
Jamie P. Motley, MS, DC, DACBR

- Professor-LCCW
- Continuing
Education Lecturer
- Private Film
Reading Practice



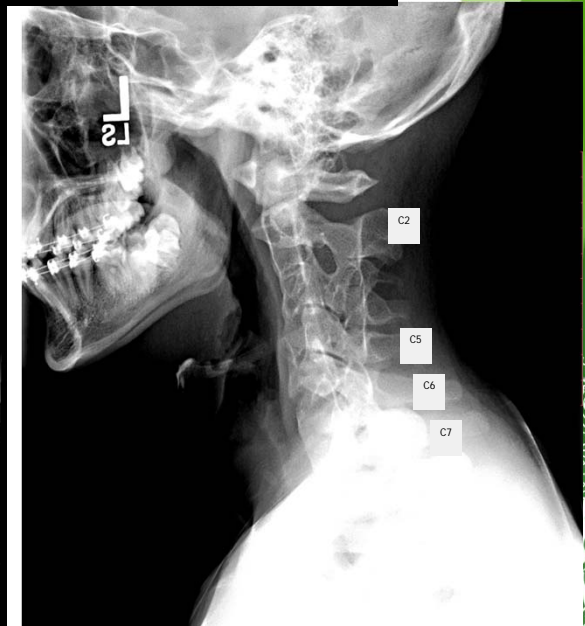
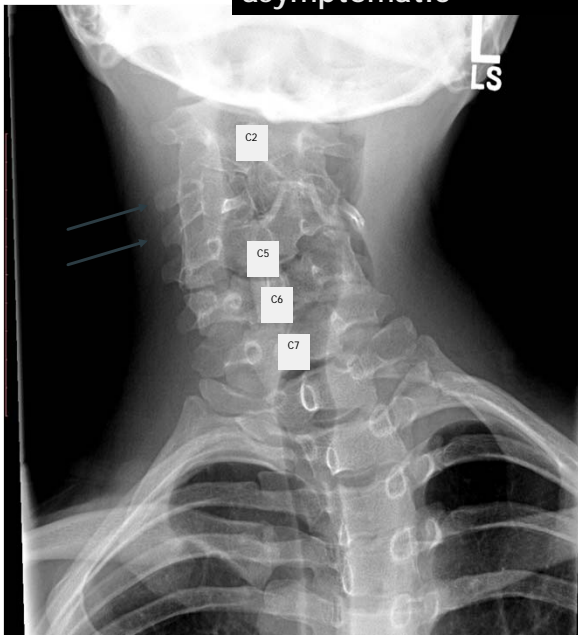
Case 3

- **Age/Gender:** 15 / M
- **History:** Visible postural deformity in cervical spine. Scoliosis evaluation. Asymptomatic



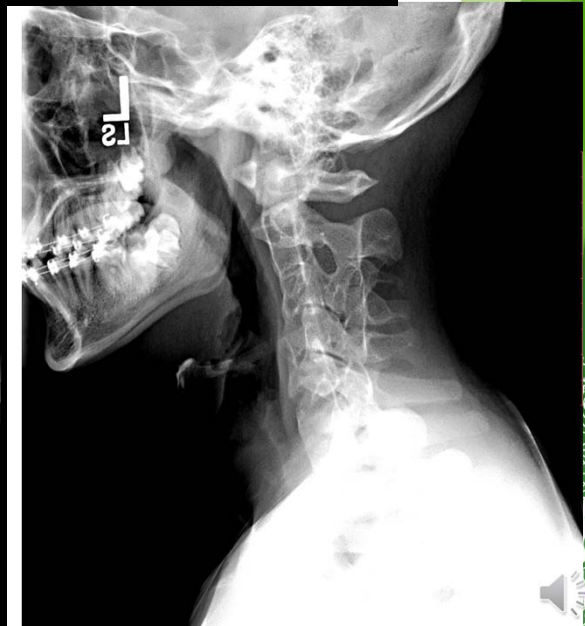
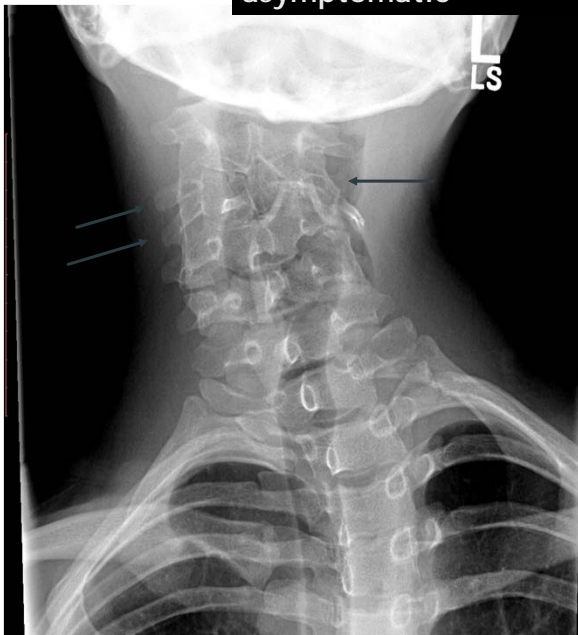IMAGING
EXAMINATION

15/M Postural abnormality. Otherwise
asymptomatic



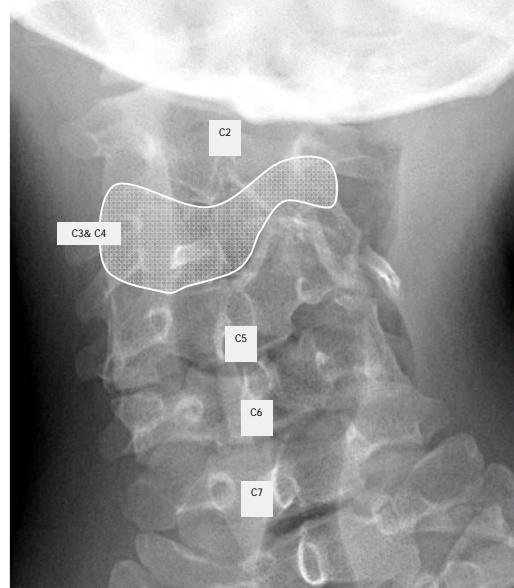
IMAGING
EXAMINATION

15/M Postural abnormality. Otherwise
asymptomatic



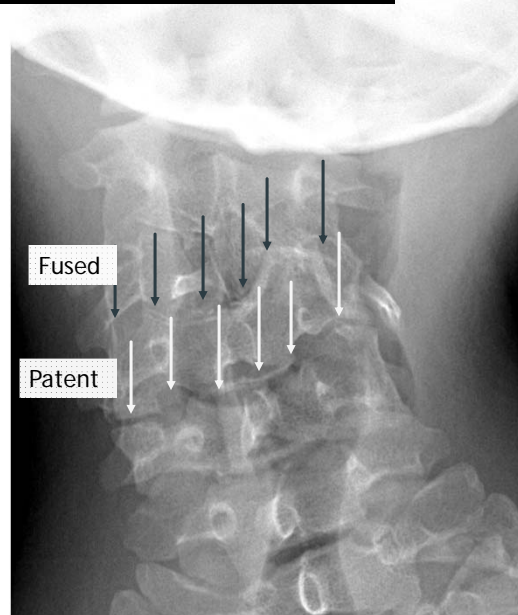
15/M Postural abnormality. Otherwise asymptomatic

- Identify Cervical Levels
- Start at C7 for Accuracy
- Determine Anomalous Anatomy
- C3 Hypoplastic with C4 Hemivertebra



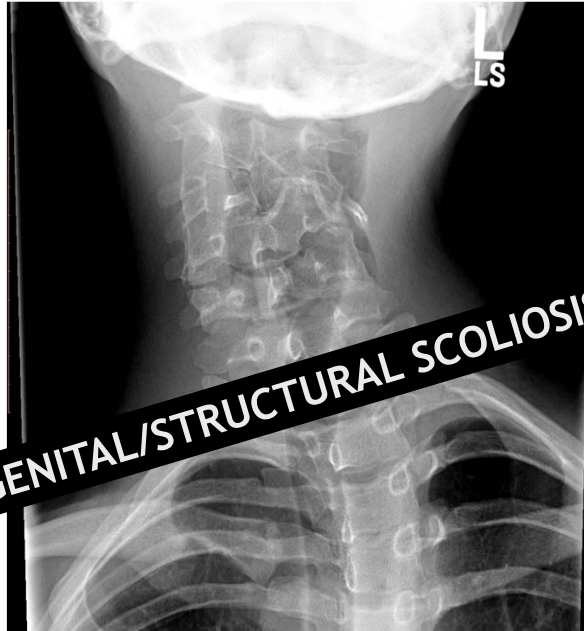15/M Postural abnormality. Otherwise asymptomatic

- Determine what levels are fused
- Determine what levels are patent



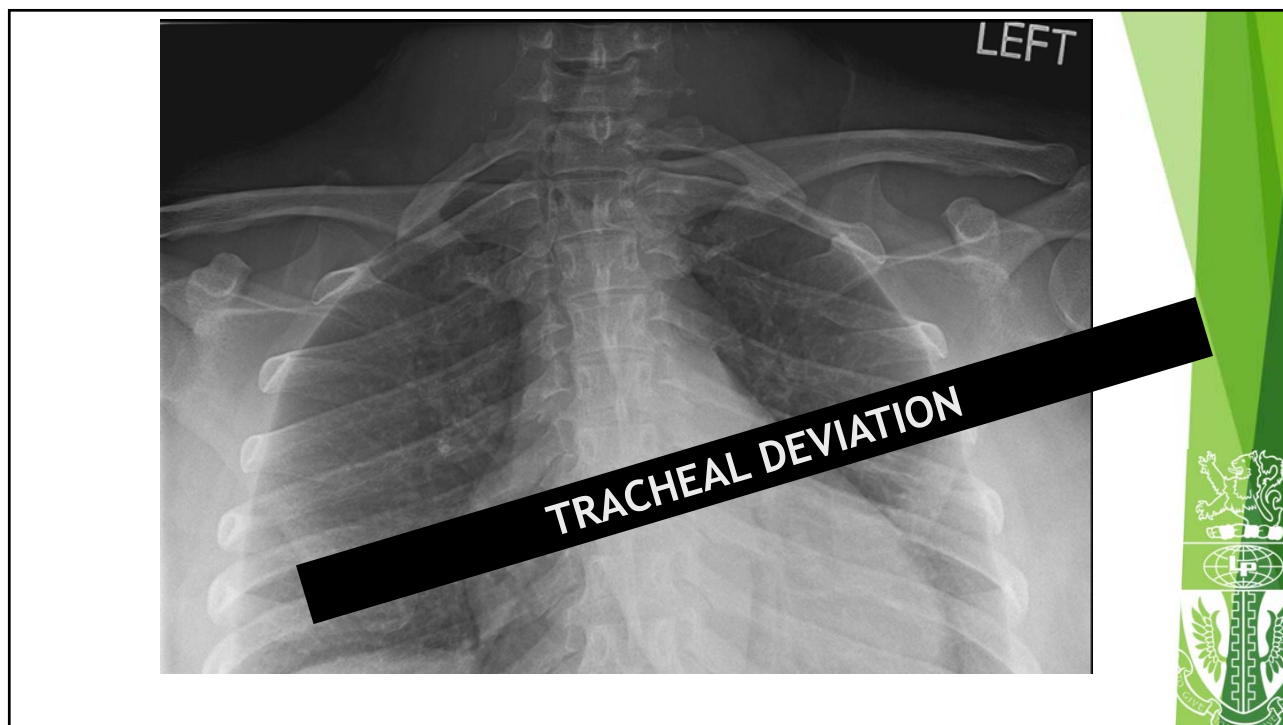
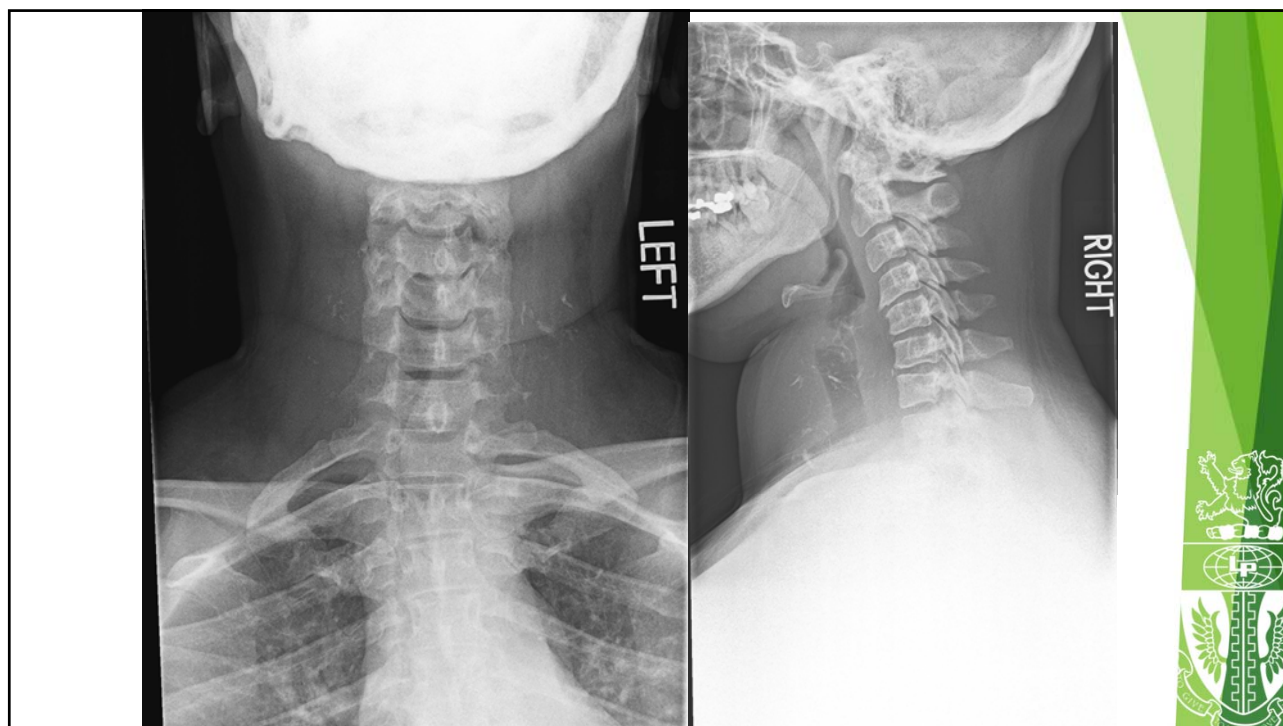
DIAGNOSIS

CONGENITAL/STRUCTURAL SCOLIOSIS



Case 4

- **Age/Gender:** 41 / M
- **History:** Anterior neck fullness. Cervical spine pain and dysfunction. No recent trauma



How to proceed?



Follow up...

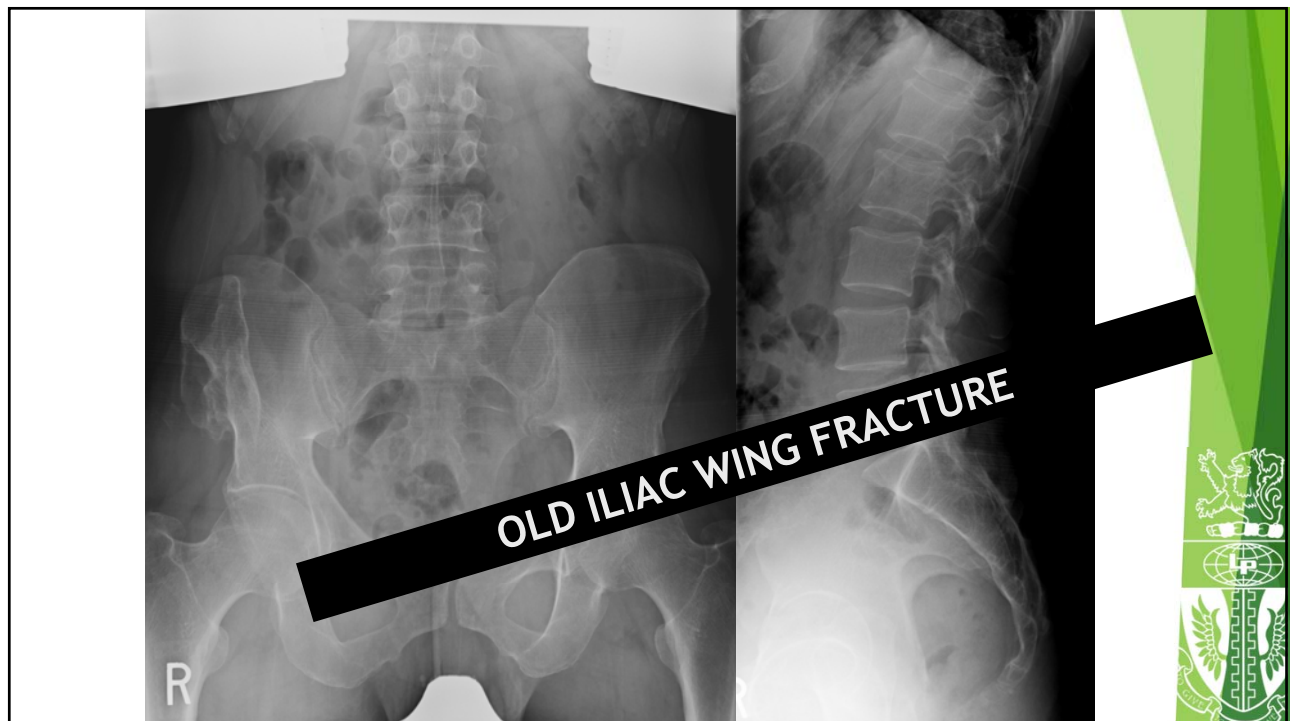
Ultrasound of anterior neck

Thyroid lab panel



Case 5

- **Age/Gender:** 43 / M
- **History:** Anterior neck fullness. Cervical spine pain and dysfunction. No recent trauma



How to proceed?



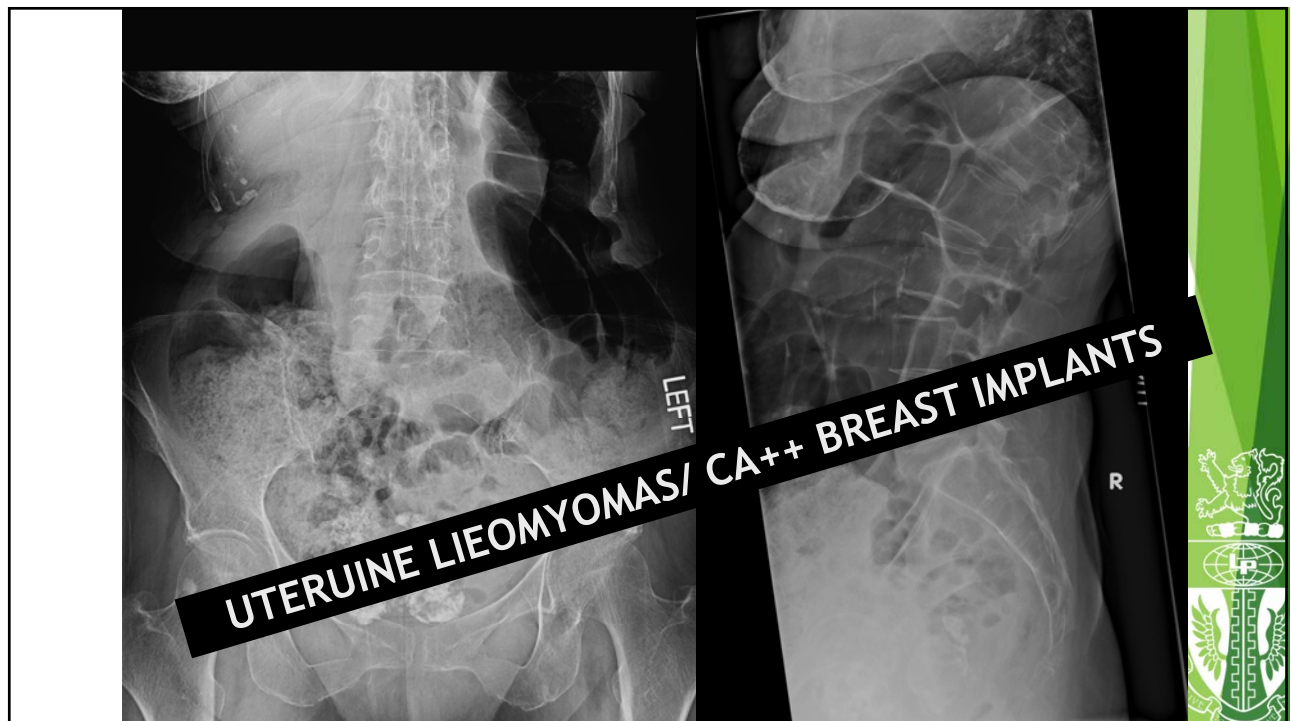Follow up...

None needed. No iliac crest contact for adjusting



Case 6

- **Age/Gender:** 75 / F
- **History:** Non-traumatic low back pain.



How to proceed?



Follow up...

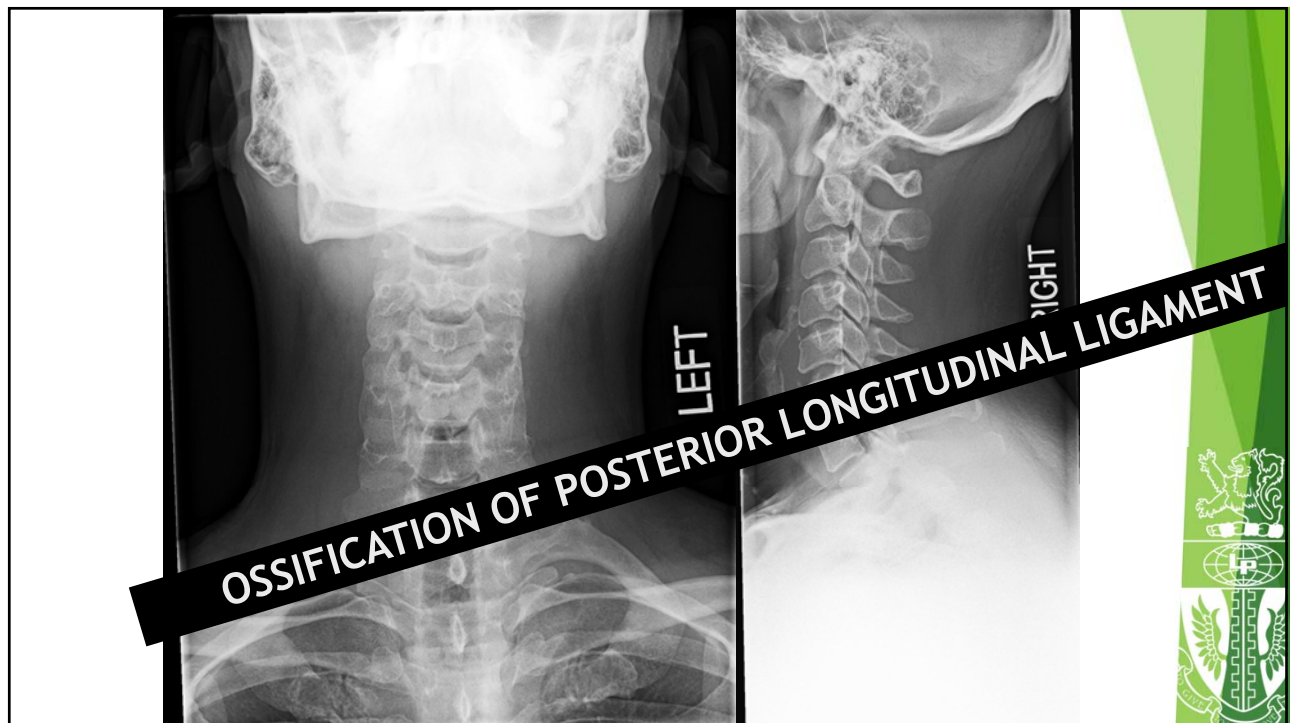
Inform gynecologist of fibroids

Surgical consultation for calcified breast implants



Case 7

- **Age/Gender:** 34 / M
- **History:** Cervicalgia with radiculopathy



How to proceed?



Follow up...

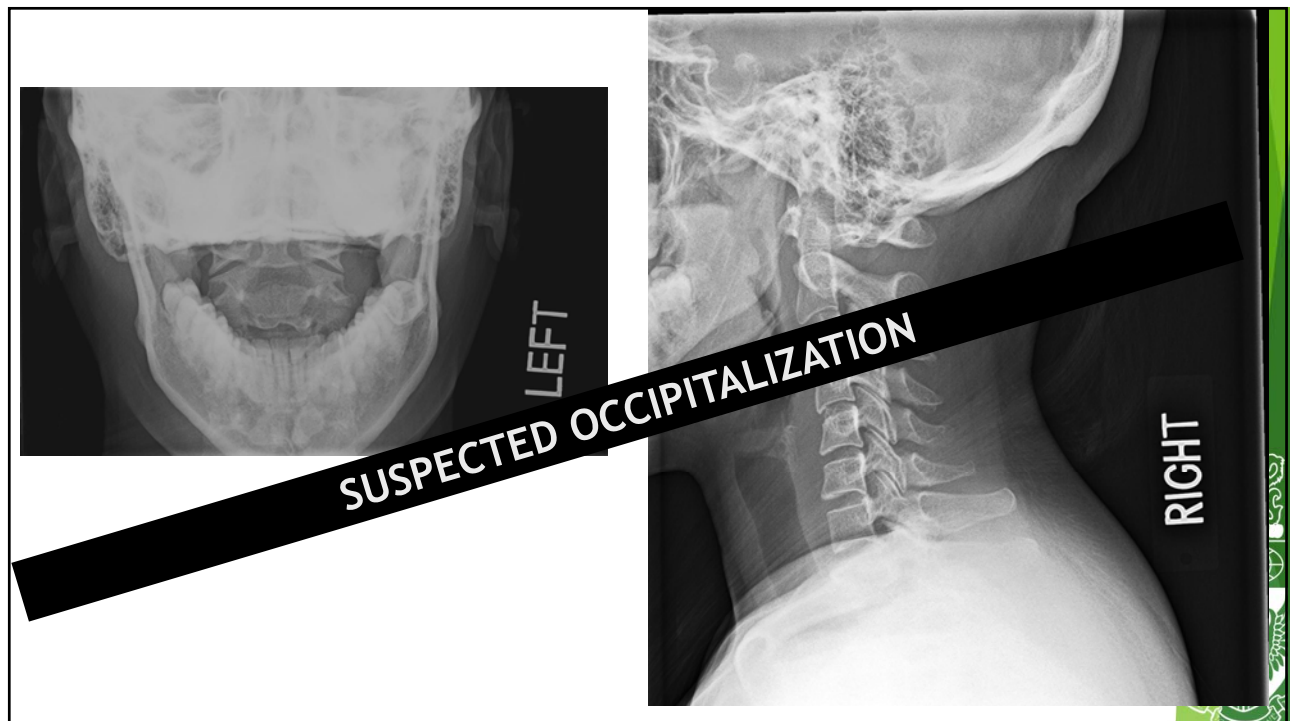
No adjustments in area of OPLL

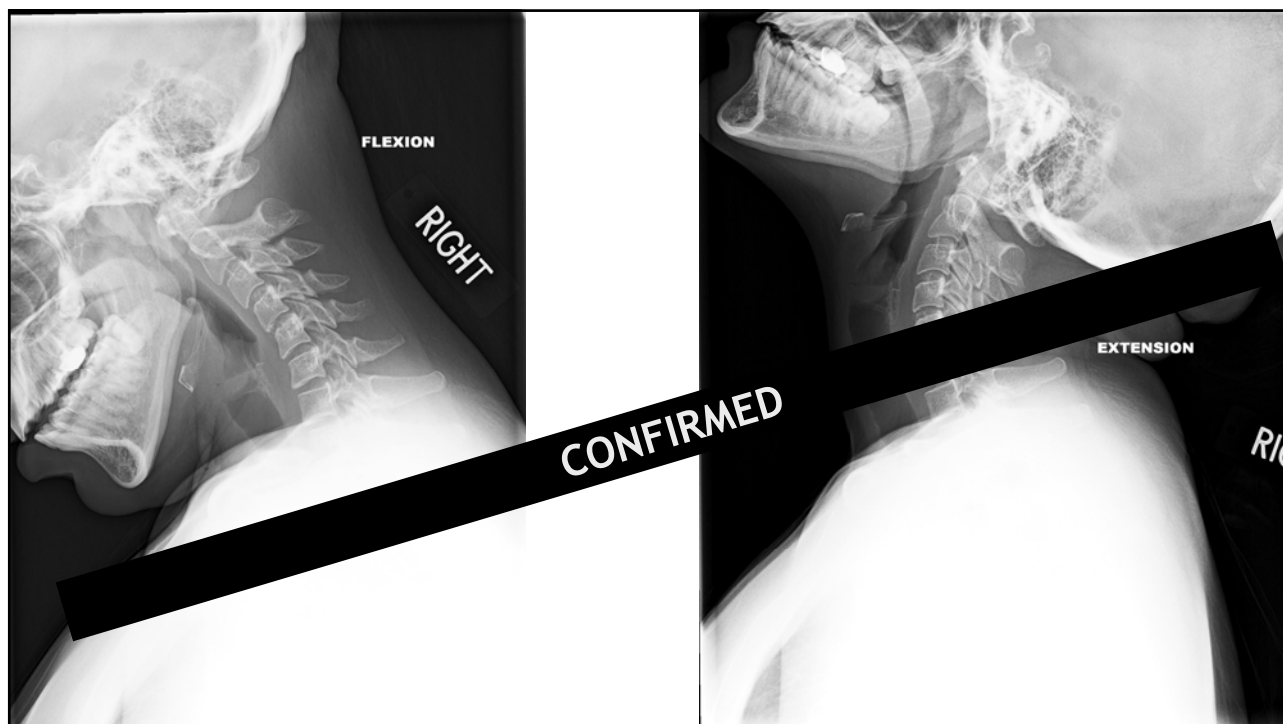
MRI of cervical spine



Case 8

- ▶ **Age/Gender:** 24 / M
- ▶ **History:** Mild cervicalgia





How to proceed?



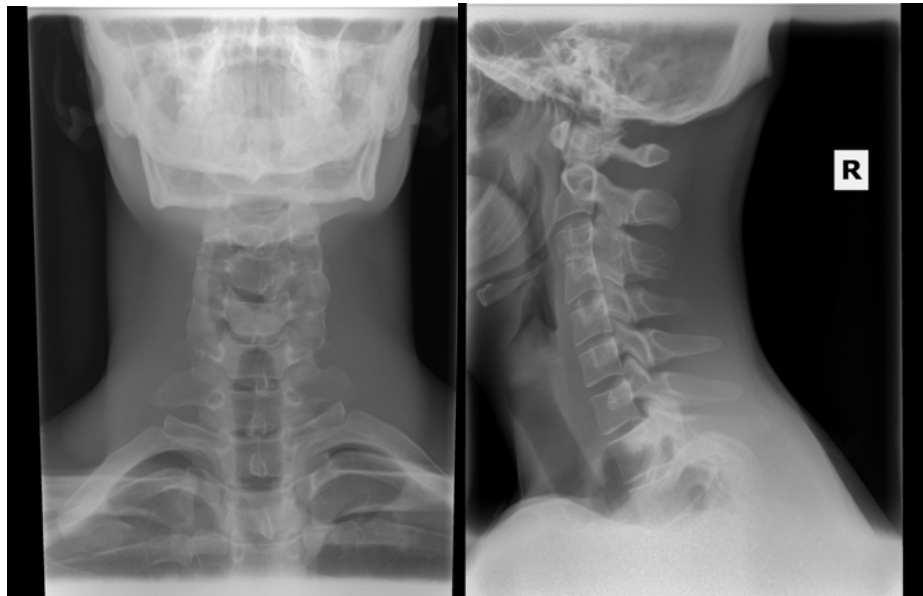
Follow up...

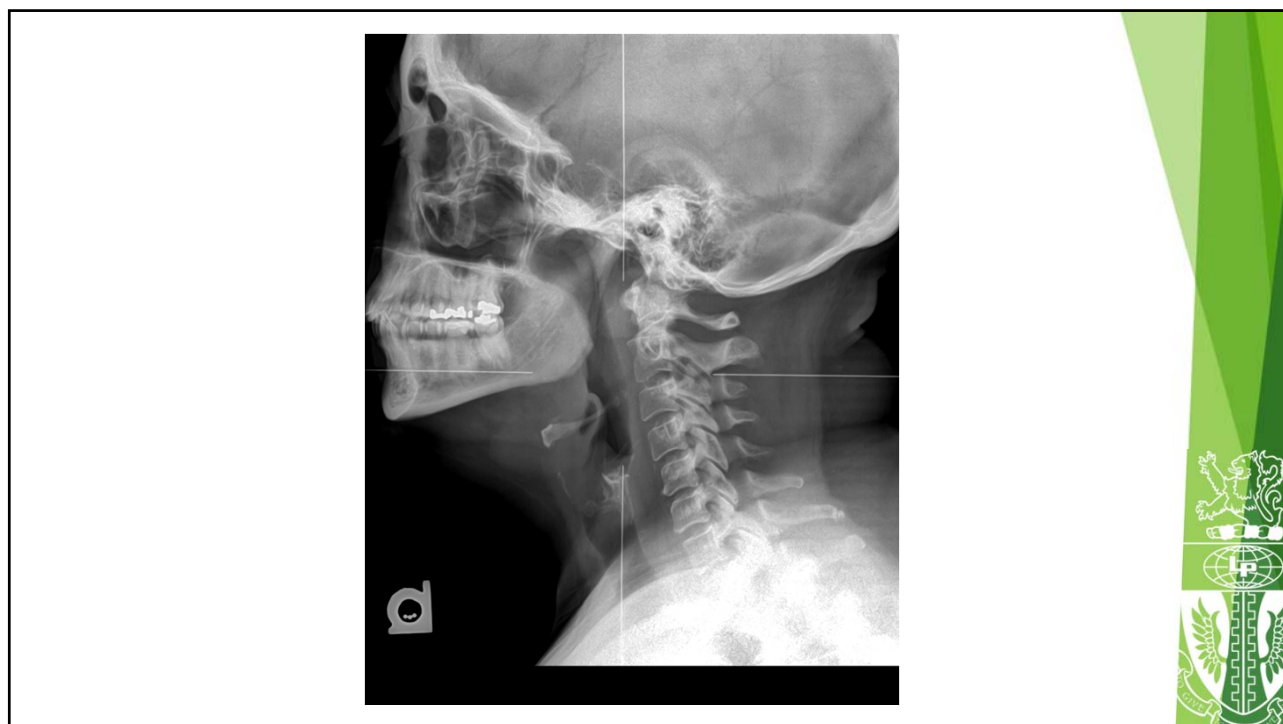C0-C1 block

Treat as single segment

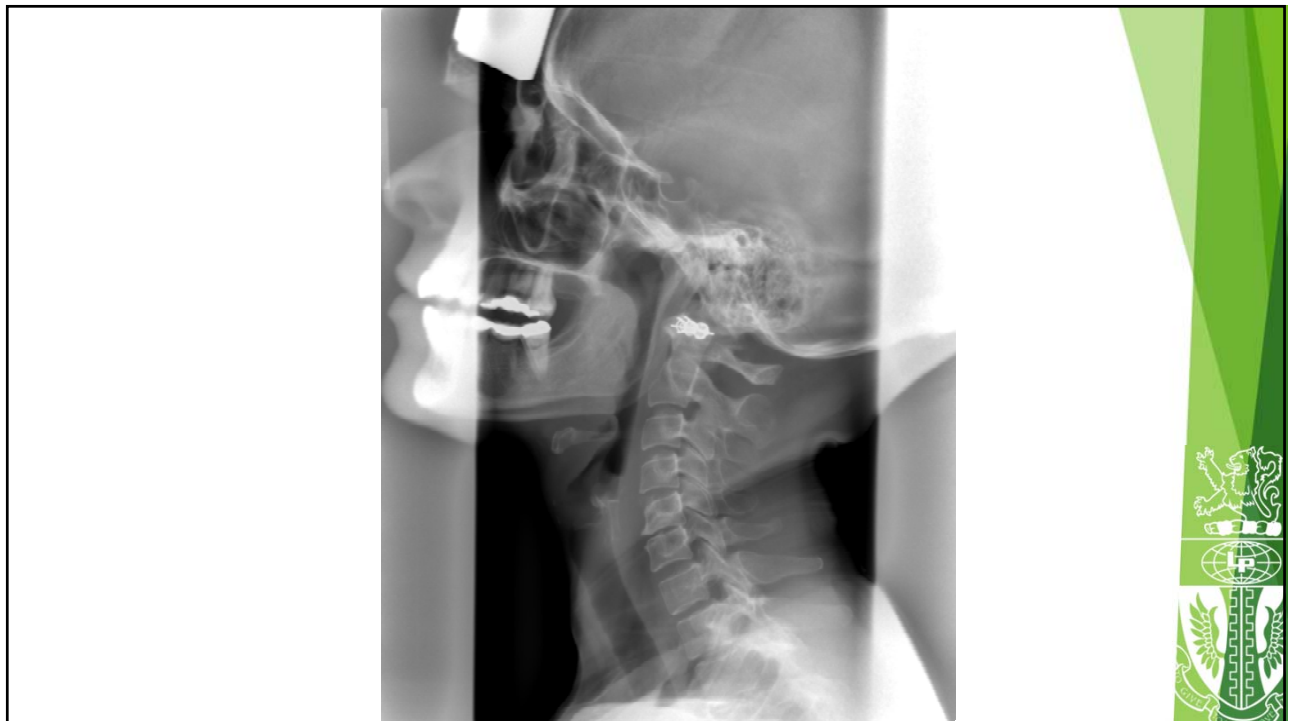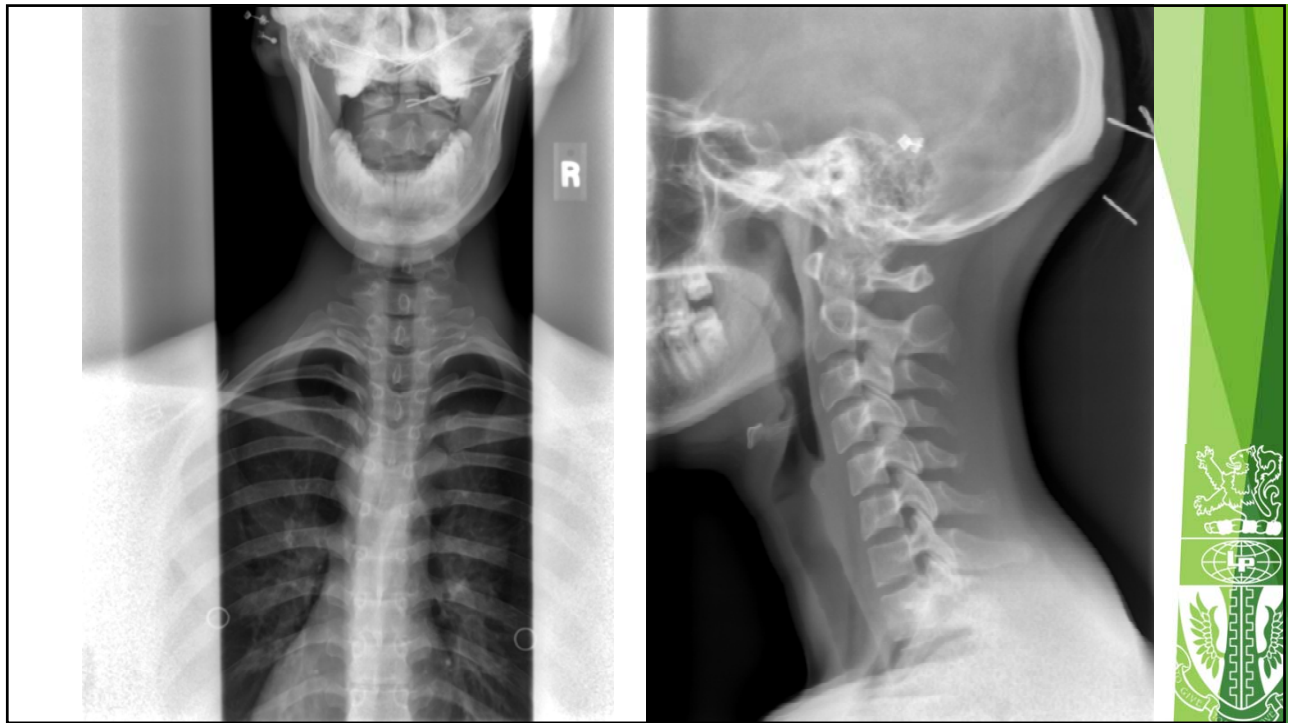


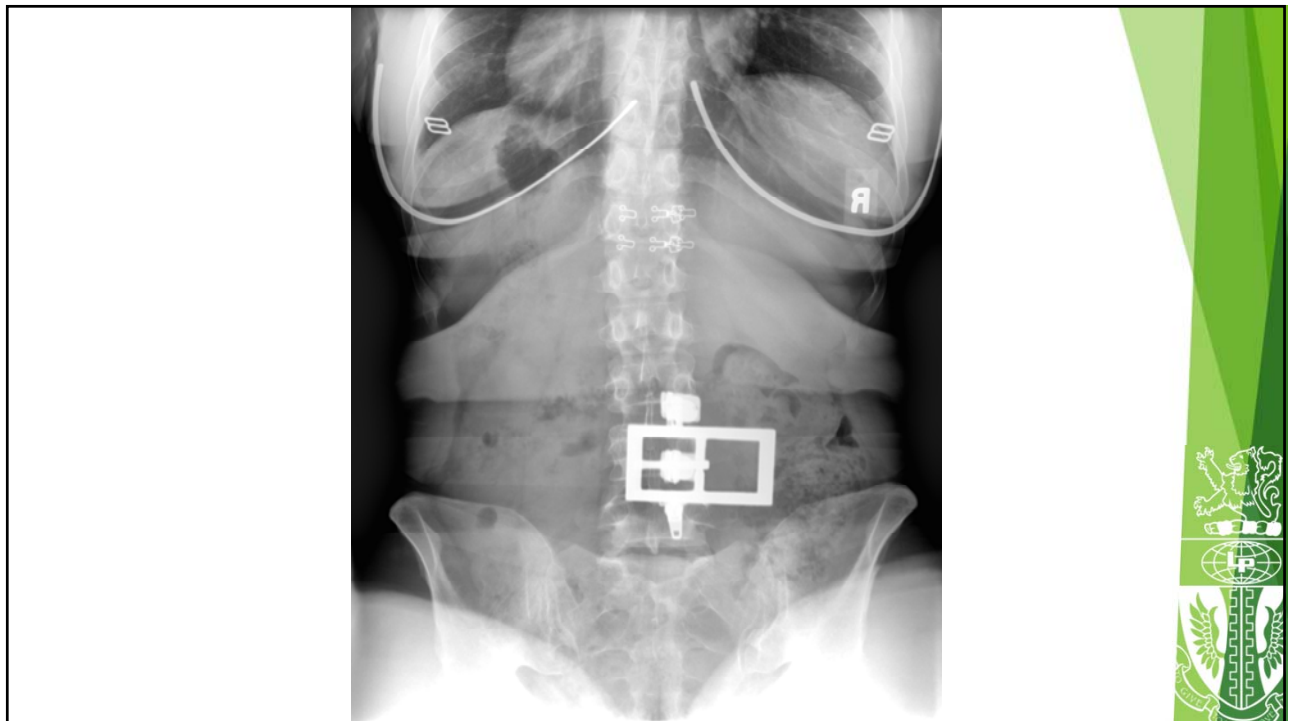
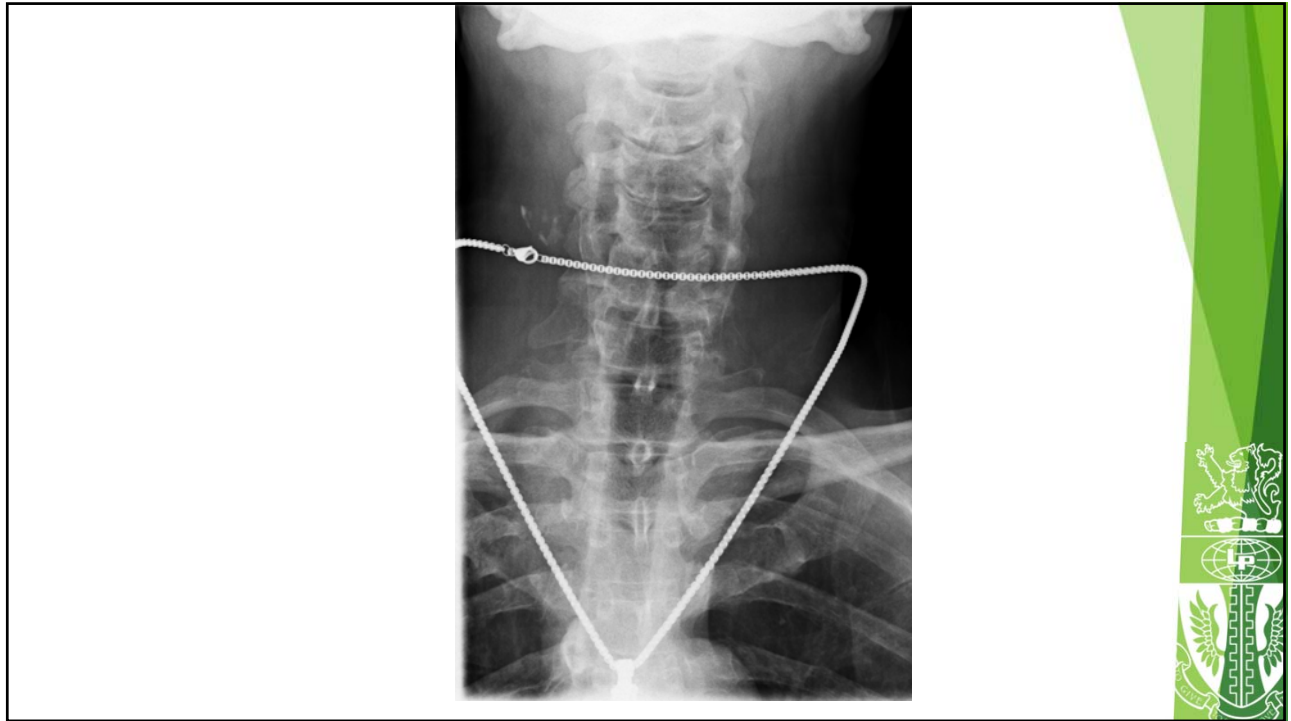
Bonus Case:

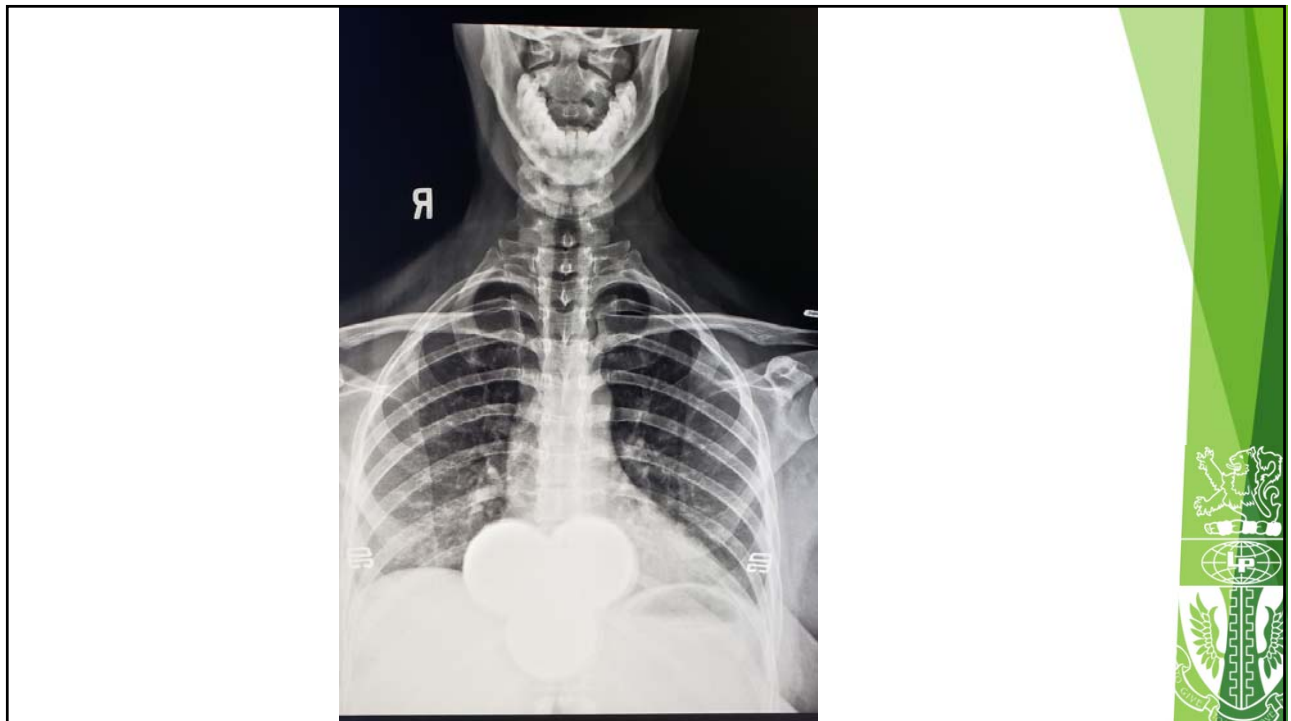
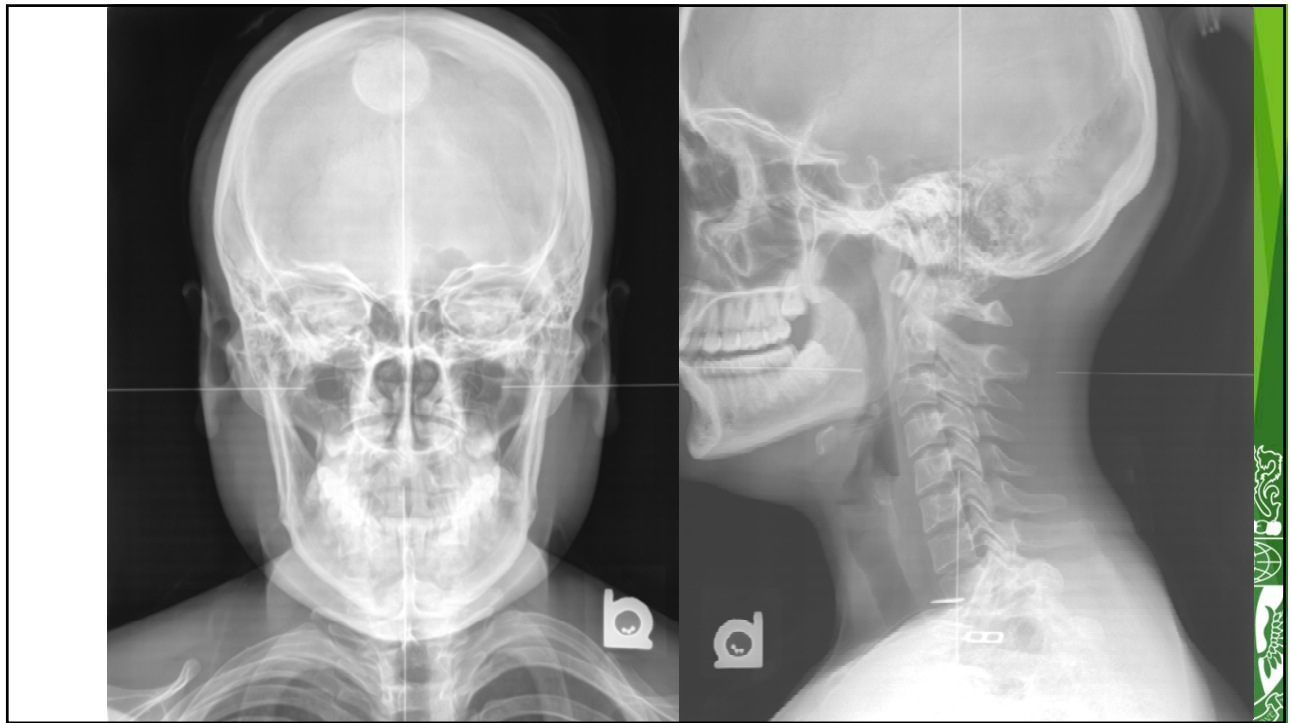


ARTIFACTS







Jamie P. Motley, MS, DC, DACBR

- ▶ Professor-LCCW
- ▶ Continuing Education Lecturer
- ▶ Private Film Reading Practice



Thank You!

Diagnostic Imaging in Chiropractic Practice The WAVE 2019

Jamie P. Motley, MS, DC, DACBR



**LIFE CHIROPRACTIC
COLLEGE WEST**

Postgraduate & Continuing Education

<http://ce.lifewest.edu> | 510.780.4508 | conted@lifewest.edu

